

Centre universitaire  
de santé McGill



McGill University  
Health Centre

**Technology Assessment Unit of the McGill  
University Health Centre (MUHC)**

# **Video Capsule Endoscopy for Obscure GI Bleeding and Crohn's Disease (Update of Report 7)**

**Report number: 60**

**DATE: June 13, 2012**

---

**Report available from <http://www.mcgill.ca/tau>**

**Report prepared for the Technology Assessment Unit (TAU)  
of the McGill University Health Centre (MUHC)**

**by**

**Xuanqian Xie and Maurice McGregor**

**Approved by the Committee of the TAU on June 4, 2012**

**TAU Committee**

**Andre Bonnici, Nandini Dendukuri, Sandra Dial,**

**Christian Janicki, Patricia Lefebvre,**

**Brenda MacGibbon-Taylor,**

**Maurice McGregor, Gary Pekeles, Guylaine Potvin,**

**Judith Ritchie, Hugh Scott, Gary Stoopler**

**Suggested citation**

Xie X, McGregor M. Video capsule endoscopy for obscure GI bleeding and Crohn's disease (Update to Report 7) Montreal (Canada): Technology Assessment Unit (TAU) of the McGill University Health Centre (MUHC); 2012 Jun 13. Report no. 60. 38 p. Available from:

[https://secureweb.mcgill.ca/tau/sites/mcgill.ca.tau/files/muhc\\_tau\\_2012\\_60\\_vce.pdf](https://secureweb.mcgill.ca/tau/sites/mcgill.ca.tau/files/muhc_tau_2012_60_vce.pdf)

---

## **ACKNOWLEDGEMENTS**

The expert assistance of the following individuals is gratefully acknowledged:

Dr. Ernest Seidman, Department of Gastroenterology, MUHC,

Mrs. Melissa Diamond, Research Manager, Digestive Lab, MUHC Research Institute

Mr. Nicolas Robert, Department of Finance, MUHC

Dr. Nandini Dendukuri, Director, Technology Assessment Unit, MUHC

## TABLE OF CONTENTS

Acknowledgements .....	i
Table of contents.....	ii
List of Figures.....	iii
Appendices .....	iii
Principal messages .....	iv
List of abbreviations .....	v
Executive summary .....	vi
Sommaire.....	ix
1. Background .....	1
2. Objective(s) .....	1
3. Methods.....	2
4. Literature review: effectiveness .....	2
4.1. Summary of results on outcomes related to efficacy and safety .....	2
4.2. Diagnostic yield of VCE versus alternatives for OGIB.....	3
4.3. Diagnostic yield of VCE versus alternatives for Crohn's disease .....	4
4.4. When should VCE be used? Evidence from Guidelines .....	4
5. Therapy at the MUHC.....	5
5.1. Overview the use of VCE .....	5
5.2. Budget impact .....	5
6. Discussion .....	6
7. Conclusions.....	7
8. Recommendations .....	7
Figures .....	9
References.....	13
Appendices .....	17

## LIST OF FIGURES

Figure 1: Forest plot of the pooled incremental diagnostic yield of VCE versus alternatives for OGIB.....	9
Figure 2: Forest plot of the pooled incremental diagnostic yield of VCE versus alternatives for Crohn's disease .....	10
Figure 3: Number of VCE procedures carried out at MUHC following internal or external requests (2008 - 2011) .....	11
Figure 4: Sub-division of externally requested VCE procedures from institutions that made at least 10 requests (2008 - 2011).....	12

## APPENDICES

Appendix 1: Literature search and study selection.....	17
Appendix 2: Results of literature search.....	18
Appendix 3: Details of diagnostic yield of VCE versus alternatives for OGIB.....	20
Appendix 4: Details of diagnostic yield of VCE versus alternatives for Crohn's disease .....	21
Appendix 5: Costs of VCE procedure.....	23

## **PRINCIPAL MESSAGES**

- **For the diagnosis of patients with small bowel disease video capsule endoscopy (VCE) is safe and provides a comparable or higher diagnostic yield than alternative diagnostic approaches.**
- **More research is needed to determine whether the higher diagnostic yield leads to better identification of clinically significant conditions, and eventually to better clinical outcomes.**
- **VCE should be available for judicious use at the McGill University Health Centre.**
- **The present practice of using it only when alternate diagnostic modalities have been tried should be maintained.**

---

## LIST OF ABBREVIATIONS

---

ASGE	American Society for Gastrointestinal Endoscopy
BAE	Balloon-assisted Enteroscopy
CI	Confidence Interval
CT	Computed Tomography
CTE	Computed Tomography Enterography/enteroclysis
DBE	Double Balloon Enteroscopy
ECCO	European Crohn's and Colitis Organisation
EGD	Esophagogastroduodenoscopy
GRADE	The Grading of Recommendations Assessment, Development and Evaluation
HTA	Health Technology Assessment
IBD	Inflammatory Bowel Disease
ICD	Implantable Cardiac Defibrillators
MGH	Montreal General Hospital
MRE	Magnetic Resonance Enterography
MRI	Magnetic Resonance Imaging
MUHC	McGill University Health Centre
OGIB	Occult Gastro-Intestinal Bleeding, that persists after a negative upper or lower endoscopy
OMED	The World Organisation of Digestive Endoscopy
OR	Odds Ratio
PE	Push Enteroscopy
RCT	Randomized Controlled Trial
RVH	Royal Victoria Hospital
SBR	Small Bowel Barium Radiography
TAU	Technology Assessment Unit
VCE	Video Capsule Endoscopy

---

## EXECUTIVE SUMMARY

### **Background**

In 2003 the Technology Assessment Unit (TAU) of the McGill University Health Centre (MUHC) recommended that Video Capsule Endoscopy (VCE) should not be approved for routine clinical practice at the MUHC. Subsequently, after an interval of 2-3 years its use at the MUHC has progressively increased. This update was requested by Mr Gary Stoopler (Administrative Director, Surgical Mission, MUHC).

### **Method**

A systematic literature search was carried out to identify Health Technology Assessment (HTA) reports, systematic reviews and clinical practice guidelines concerning the use of VCE in patients with OGIB or Crohn's diseases. We calculated the budget impact of VCE based on MUHC costs estimates.

### **Results: Literature review**

We identified fourteen systematic reviews and 3 HTAs. All of these found that VCE has a significant diagnostic yield in patients with OGIB and Crohn's disease. We based the following summary on the evidence from 4 meta-analyses that most appropriately addressed the questions at issue.

#### ***Diagnostic yield of VCE versus alternatives for OGIB***

In Leighton et al, the incremental yield of VCE compared to push enteroscopy was 30% (95% CI: 21%, 38%) in favour of VCE; and 36% (95% CI: 25%, 48%) favouring VCE compared to small bowel barium radiography. In the meta-analysis by Teshima et al. the pooled yield for VCE and double balloon enteroscopy was 62% (95%CI: 47%, 76%) and 56% (95%CI: 49%, 62%), respectively, with an odds ratio (OR) of 1.39 (95%CI: 0.88, 2.20).

#### ***Diagnostic yield of VCE versus alternatives for Crohn's disease***

Dionisio et al. reported several meta-analyses based on patients with suspected or established Crohn's disease. The pooled incremental diagnostic yield of VCE compared to different alternatives was as follows: i) small bowel barium radiography (SBR): 37% (95% CI 29%, 45%); ii) CT enterography / enteroclysis (CTE): 39% (95% CI 27%, 50%); iii) colonoscopy and ileoscopy: 15% (95% CI 7%, 24%); iv) push enteroscopy: 42% (95% CI 31%, 53%); v) magnetic resonance enterography (MRE): 7% (95% CI -4%, 17%). The diagnostic yield of VCE for patients with established Crohn's disease was higher than that for patients with suspected Crohn's disease.



**Safety**

The only potentially serious complication of VCE is capsule retention. A meta-analysis by Liao et al reported that the pooled retention rate was 1.4% across 150 studies.

**The use of VCE at the MUHC**

VCE is currently used for diagnosis of occult GI bleeding (70%), Crohn's disease (25%) and other indications (5%) at the MUHC. The estimated capsule retention rate is 0.5%. The number of VCE procedures has increased from 55 in 2008 to 96 in 2010, with 87 in the first half of 2011. Overall, there were 126 internal requests and 215 external requests.

**Budget impact**

The estimated unit cost of each VCE is approximately \$984.55. Thus the gross cost of VCE to the MUHC for approximately 100 cases in fiscal year 2011 would be \$98,455.

**CONCLUSIONS**

- **The present evidence is consistent that for the diagnosis of patients with small bowel disease VCE provides a comparable and sometimes higher diagnostic yield than alternative diagnostic approaches.**
- **For patients with OGIB, the diagnostic yield of VCE is significantly higher than that of push enteroscopy, and small bowel barium radiography, and not significantly different from that of double balloon enteroscopy.**
- **For patients with suspected and established small-bowel Crohn's Disease, the diagnostic yield of VCE is significantly higher than that of small bowel barium radiography, CT enterography/enteroclysis, colonoscopy with ileoscopy and push enteroscopy. There is no statistically significant difference in yield between VCE and MRE enterography.**
- **In spite of the absence of data it must be noted that VCE may be associated with overdiagnosis. Two RCTs have demonstrated that compared with other diagnostic tests, VCE did not significantly improve the clinical outcomes in 1 year follow-up.**
- **While the optimal sequence of diagnostic tests must be determined for each case, there is agreement that VCE should not be a first line test.**
- **The unit cost to the MUHC of each VCE study is estimated to be \$984.55. The budget impact of the projected 100 tests per year would therefore be \$98,455. Its use will reduce demand on alternative test procedures, thus diminishing wait times.**

## **RECOMMENDATIONS**

- **VCE is now a fully established test for the diagnosis of patients with small bowel disease. It should be available for judicious use at the MUHC. The present practice of using it only when alternate diagnostic modalities have been tried should be maintained.**
- **Due to the substantial budget impact and consequent opportunity costs of a technology which cannot in many cases be justifiably refused, government should be approached with a special request to provide budgetary compensation.**

## SOMMAIRE

### **Contexte**

En 2003, l'Unité d'évaluation des technologies (Technology Assessment Unit (TAU)) du Centre universitaire de santé McGill (CUSM) recommanda que la vidéo endoscopie par capsule (VEC) ne devrait pas être approuvée pour la pratique clinique de routine au CUSM. Par la suite, après une période de 2-3 ans, son utilisation au CUSM a progressivement augmentée. Cette mise à jour nous a été demandée par M. Gary Stoopler (directeur administratif, mission chirurgicale, CUSM).

### **Méthodologie**

Une recherche systématique de la littérature fut menée pour identifier des rapports d'évaluation des technologies, des revues systématiques ainsi que des guides de pratique clinique concernant l'utilisation de la VEC chez les patients souffrant de saignements gastro-intestinaux occultes (SGIO) ou de la maladie de Crohn. Nous avons calculé l'impact budgétaire de la VEC à partir des estimations de coûts au CUSM.

### **Résultats. Revue de la littérature**

Nous avons identifié quatorze revues systématiques ainsi que 3 rapports d'évaluation technologique. Toutes ces publications soulignaient que la VEC a un apport diagnostique significatif chez les patients souffrant de SGIO et de la maladie de Crohn. Le résumé qui suit se base sur les preuves des 4 méta-analyses qui concernent spécifiquement la question en jeu.

#### ***Apport diagnostique de la VEC versus les approches alternatives pour les SGIO***

Leighton et al publièrent que l'apport additionnel de la VEC comparativement à l'entéroscopie poussée était de 30% (95% CI: 21%, 38%) favorisant la VEC; de même, l'apport additionnel de la VEC par comparaison à la radiographie au bariem de l'intestin grêle était de 36% (95% CI: 25%, 48%) en faveur de la VEC. Teshima et al, suite à une méta-analyse, mentionnèrent que l'apport de la VEC et de l'entéroscopie à double ballons était de 62% (95% CI: 47%, 76%) et de 56% (95% CI: 49%, 62%), respectivement, avec un OR de 1,39 (95% CI: 0,88 - 2,20).

## ***Apport diagnostique de la VEC versus les approches alternatives pour la maladie de Crohn***

Dionisio et al ont rapporté plusieurs méta-analyses impliquant des patients chez qui l'on soupçonnait la maladie de Crohn ou qui en étaient affectés. L'apport diagnostique additionnel sommatif de la VEC comparé à différentes alternatives était le suivant: i) 37% (95% CI: 29%, 45%) par rapport à la radiographie au barium de l'intestin grêle; ii) 39% (95% CI: 27%, 50%) par rapport à la tomographie axial (CT scan) entérographique/entéroclyse; iii) 15% (95% CI: 7%, 24%) par rapport à la colonoscopie et l'iléoscopie; iv) 42% (95% CI: 31%, 53%) par rapport à l'entéroscopie poussée et v) 7% (95% CI: -4%, 17%) par rapport à l'entérographie par résonance magnétique. L'apport diagnostique de la VEC était supérieur chez les patients affectés par la maladie de Crohn que chez les patients où l'on soupçonnait la présence de cette maladie.

### **Innocuité**

La seule complication potentiellement grave de la VEC est la rétention de la capsule. Une méta-analyse publiée par Liao et al rapportait un taux de rétention sommatif de 1,4% parmi 150 études.

### **L'utilisation de la VEC au CUSM**

La VEC est couramment utilisée au CUSM pour le diagnostic des saignements gastro-intestinaux occultes (70%), de la maladie de Crohn (25%) et pour d'autres indications (5%). Le taux estimé de rétention de la capsule est de 0,5%. Le nombre de procédures de VEC est passé de 55 en 2008 à 96 en 2010; pour la première moitié de 2011, on note 87 procédures. Globalement, il y avait 126 requêtes internes et 215 requêtes externes.

### **Impact budgétaire**

Le coût d'une seule procédure de VEC est d'environ 984,55 \$. Par conséquent, le coût brut pour le CUSM des procédures de VEC pour environ 100 cas pour l'année fiscale 2011 sera de 98 455 \$.

## **CONCLUSIONS**

- **La preuve actuelle supporte l'énoncé que pour le diagnostic des patients souffrant de maladies à l'intestin grêle, la VEC permet un apport diagnostique comparable et parfois supérieur aux approches diagnostiques alternatives.**
- **Pour les patients souffrant de SGIO, l'apport diagnostique de la VEC est significativement plus élevé que celui de l'entéroscopie poussée, de la radiographie au barium de l'intestin grêle, mais pas significativement différent de celui de l'entéroscopie à double ballons.**
- **Pour les patients chez qui l'on soupçonne la maladie de Crohn à l'intestin grêle ou déjà diagnostiquée, l'apport diagnostique de la VEC est significativement plus élevé que celui de la radiographie au barium de l'intestin grêle, celui de l'angiographie axiale entérographique/entéroclyse, celui de la colonoscopie avec iléoscopie et celui de l'entéroscopie poussée. Il n'y a pas de différence statistiquement significative entre les apports diagnostiques de la VEC et de l'entérographie par résonance magnétique.**
- **Malgré l'absence de données, il est à noter que la VEC peut être associée à un surdiagnostic. Deux études randomisées ont démontré que, comparée à d'autres tests diagnostiques, la VEC n'avait pas amélioré de façon significative les résultats cliniques après un suivi d'une année.**
- **Bien que la planification optimale des tests diagnostiques doit être déterminée pour chaque cas, il y a consensus à l'effet que la VEC ne devrait pas être le premier test.**
- **Pour le CUSM, le coût d'une seule procédure de VEC est évalué à 984,55\$. L'impact budgétaire des 100 tests projetés par année est donc de 98 455\$. Son utilisation diminuera la demande pour des procédures alternatives, réduisant ainsi les temps d'attente.**

## **RECOMMANDATIONS**

- **La VEC est maintenant un test reconnu pour le diagnostic des patients souffrant de maladies à l'intestin grêle. Ce test devrait être disponible pour une utilisation judicieuse au CUSM. La pratique actuelle voulant que ce test**

**soit utilisé uniquement lorsque d'autres modalités diagnostiques alternatives aient été utilisées, doit être maintenue.**

- **Étant donné l'impact budgétaire important ainsi que les coûts d'opportunité d'une technologie qu'on ne peut légitimement refuser dans plusieurs cas, des démarches devraient être entamées auprès du gouvernement pour obtenir une compensation budgétaire.**

# Video Capsule Endoscopy for Obscure GI Bleeding and Crohn's Disease (Update of Report 7)

## 1. BACKGROUND

In 2003 the Technology Assessment Unit (TAU) of the McGill University Health Centre (MUHC) carried out an evaluation of Video Capsule Endoscopy (VCE)<sup>1</sup>. At that time the evidence of its efficacy was weak and the acquisition cost relatively high, and it was recommended that this technology should not yet be approved for routine clinical practice at the MUHC. Subsequently, numerous studies of VCE have been carried out, acquisition costs have fallen, the test has become widely accepted, and its use at the MUHC has progressively increased. As a result, the TAU was requested by Mr Gary Stoopler (Administrative Director, Surgical Mission, MUHC) to undertake an update of the previous report, and to make recommendations on the future use of VCE at the MUHC.

VCE has been increasingly used in clinical practice since 2001<sup>2</sup> when Given® Capsule Endoscopy<sup>3</sup> was granted approval in Canada, United States, and the European Union. The device consists of a capsule measuring 11mm x 26mm, housing an optical dome, lens, illuminating disk, imager, battery, transmitter and antenna<sup>1</sup>. Once ingested, the capsule passes through the digestive system, transmitting the images and data to a data recorder carried on a belt worn by the patient. Patients can carry out normal activities during the procedure. On completion of recording, the images are downloaded for review and the capsule is excreted with a bowel movement, usually within 24 hours<sup>3</sup>. More details of VCE procedures can be found in our previous report<sup>1</sup> and in the website of the manufacturer<sup>3</sup>.

According to the manufacturer over 1,200,000 PillCam VCE procedures have now been carried out worldwide<sup>3</sup>. Although in recent years VCE has been used to detect diseases, such as, Barrett's esophagus, colorectal polyps, neuroendocrine tumours, celiac disease and Peutz Jeghers syndrome, its principal use is to identify the site and cause of occult gastrointestinal bleeding (OGIB) (i.e. bleeding that is not apparent to the patient), and to identify Crohn's disease. The following report will focus on these two applications. Although a number of studies now report extension of the use of VCE to paediatric patients<sup>4-6</sup> we will here consider adult use only.

## 2. OBJECTIVE(S)

- To determine the efficacy and safety of VCE for the identification of occult gastrointestinal bleeding (OGIB) and Crohn's disease.
- To estimate the budget impact of use of VCE at the MUHC.

### 3. METHODS

A systematic literature search was carried out using Pubmed and the Health Technology Assessment (HTA) database of the Centre for Reviews and Dissemination<sup>7</sup> of York University to identify HTA reports, systematic reviews and clinical practice guidelines concerning the use of VCE in patients with OGIB or Crohn's disease. The details of the keywords used in the search and the process of study selection are reported in Appendix 1.

Data concerning the use and costs of VCE at MUHC were supplied by Mrs Melissa Diamond, Research Manager, Digestive Lab, MUHC Research Institute. All costs were expressed in 2012 Canadian Dollars<sup>8</sup>.

### 4. LITERATURE REVIEW: EFFECTIVENESS

We identified fourteen systematic reviews<sup>9-22</sup> and 3 HTAs<sup>23-25</sup> relating to the use of VCE in the diagnosis of small bowel diseases. Although the level of evidence supporting the use of VCE is relatively low<sup>26</sup>, all of these have consistently found that VCE has a significant diagnostic yield in patients with OGIB and Crohn's disease. We based the following observations on the evidence from 4 meta-analyses<sup>9-11;20</sup> that most appropriately addressed the questions at issue. The title, author and publishing year of the remaining systematic reviews and HTA can be found in Appendix 2. We also identified 2 guidelines for the management of OGIB<sup>27-29</sup> and two for Crohn's disease<sup>30;31</sup>.

#### 4.1. Summary of results on outcomes related to efficacy and safety

##### 4.1.1. Completion of the examination

Complete examination of the small intestine, (defined as passage of the capsule, while functioning, through the ileocecal valve with excretion within 2 weeks), is not always achieved. Liao et al. reviewed 227 reports involving 22,840 VCE procedures published from 2000 to 2008 concerning the use of VCE for small bowel diseases<sup>9</sup>. In the 142 studies (11,979 procedures) that reported completion rates, the overall pooled completion rate and 95% confidence interval (CI) was 83.5% (82%, 85%). The pooled completion rates for the indication of OGIB and Crohn's disease were 83.6% (80.9%, 86%) and 85.4% (79%, 90.8%), respectively. Battery exhaustion, capsule retention, technical failure and poor small-bowel preparation were the main reasons causing incomplete examination.

##### 4.1.2. Safety

The only potentially serious complication of VCE is capsule retention. Liao et al<sup>9</sup> defined this as a capsule remaining in the digestive tract for 2 weeks or more, or the



patient's requiring intervention to aid its passage. Based on 150 studies reporting on capsule retention rate, the pooled retention rate was 1.4%. Removal of the retained capsule was by surgery (59%) spontaneous excretion with or without medications (15.8%), and endoscopy (12.5%). Thus, approximately 1% of VCE tests required additional surgical or endoscopic intervention. No other complications were reported.

#### **4.1.3. Detection Rate**

Due to the absence of a gold standard, no estimates of sensitivity or specificity of VCE were provided in the meta-analyses identified. Instead, authors reported the detection rate, or diagnostic yield, which is the ratio of the number of positive detections divided by the total number of VCE procedures. This figure is clearly determined as much by the selection criteria as by the sensitivity of the test.

In the study of Liao et al<sup>9</sup> the pooled detection rate was 59.4% (95% CI 56.5%, 62.2%) for all procedures. The pooled detection rates for the indication of OGIB and Crohn's disease were 60.5% (95% CI 57.2%, 63.9%) and 55.3% (95% CI 48%, 62.4%), respectively. Common clinically significant findings for OGIB were angiodysplasia (50%), followed by inflammatory/ulcers (26.8%) and neoplastic lesions (8.8%).

## **4.2. Diagnostic yield of VCE versus alternatives for OGIB**

The relative efficacy of VCE has been the objective of two meta-analyses. In 2006 Leighton et al. carried out a meta-analysis of prospective studies that compared the rates of clinically significant findings with the use of VCE with other diagnostic technologies in the diagnosis of OGIB<sup>20</sup>. Clinically significant findings were defined as those that identified the definite or probable source of OGIB. The *incremental diagnostic yield* was defined as the difference between the yield of VCE and that of other tests. The authors identified 20 studies, including 9 abstracts, comparing VCE with push enteroscopy, small bowel barium radiography, intraoperative endoscopy, mesenteric angiography, computed tomography (CT) enteroclysis and small bowel magnetic resonance imaging (MRI).

Teshima et al. 2011 compared VCE with double balloon enteroscopy (DBE)<sup>11</sup>. After exclusion of 4 studies in which DBE was only performed in patients with positive VCE results, they identified 10 studies, 7 prospective and 3 retrospective, enrolling 193 patients.

The findings on incremental diagnostic yield from these two meta-analyses are summarised in Figure 1. VCE was found to have a higher diagnostic yield compared to most alternatives and a similar diagnostic yield compared to others. More details on the percentage of diagnostic yield obtained with each technology appear in Appendix 3.

### **4.3. Diagnostic yield of VCE versus alternatives for Crohn's disease**

Dionisio et al. systematically reviewed the diagnostic yield of VCE in adult patients with suspected and established small-bowel Crohn's disease<sup>10</sup>. Their review included 19 prospective studies, including 17 manuscripts and 2 abstracts. The authors compared the diagnostic yield of VCE with small bowel barium radiography (SBR), CT enterography/enteroclysis (CTE), colonoscopy with ileoscopy, push enteroscopy, and MR enterography. Due to the absence of independently validated criteria for diagnosis of CD with VCE, the definitions of positive findings were determined by the authors of individual studies. Their results on incremental diagnostic yield are summarized in Figure 2. We can see that VCE has a higher diagnostic yield compared to most alternatives and a comparable diagnostic yield to others. Details of the diagnostic yield associated with the individual technologies appear in Appendix 4.

### **4.4. When should VCE be used? Evidence from Guidelines**

From the above it is evident that in diagnostic yield VCE is the equivalent of, or superior to, the available alternative procedures. However, the selection of the appropriate diagnostic test will depend on numerous factors (including age, the prior endoscopic evaluation, nasogastric tube aspirates, the overt or occult status of bleeding) that can only be properly assessed in the context of a particular case.

American Society for Gastrointestinal Endoscopy (ASGE) standards of practice committee presented a guideline for the management of OGIB in 2010<sup>27</sup> VCE was mentioned as a possible diagnostic option for patients with non-upper GI bleeding following negative esophagogastroduodenoscopy (EGD) or push enteroscopy and for patients with recent overt OGIB but without ongoing bleeding. In patients with occult OGIB, in the absence of localizing signs or symptoms, VCE was recommended as the first line diagnostic test to evaluate the small bowel in the absence of contraindications. The level of evidence supporting these recommendations ranged from low to moderate, if at all specified.

The World Organisation of Digestive Endoscopy (OMED) and the European Crohn's and Colitis Organisation (ECCO) supported the publication of a guideline of small-bowel endoscopy in the management of patients with inflammatory Bowel Disease (IBD)<sup>30</sup> in 2009. This guideline suggests that VCE be used with other imaging modalities to diagnose suspected Crohn's disease. Most established Crohn's disease patients have lesions located in the (neo)terminal ileum, accessible by ileocolonoscopy. For these patients, it is not necessary to perform an additional small-bowel endoscopy. It was recommended that VCE be used in patients with unexplained symptoms and inconclusive radiographic imaging, if this may change the therapeutic management, though this recommendation was based on poor quality of evidence (Level 5 based on Oxford Centre for Evidence Based Medicine)

The risk of capsule retention is an important consideration in patient's with established Crohn's disease.

## 5. THERAPY AT THE MUHC

### 5.1. Overview the use of VCE

The following details were obtained from Dr. Ernest Seidman.

**Indications.** At the MUHC, VCE is currently used for the following.

- In 70% of patients it is used in the diagnosis of occult GI bleeding. Patients have typically already been through gastroscopy and colonoscopy, as well as other conventional diagnostic technologies, such as angiography and CT.
- In 25% of patients it is used to diagnose Crohn's disease that could not be detected by colonoscopy or imaging.
- 5% of patients have assorted problems, such as unexplained diarrhea.

**Complications.** Capsule retention is the major adverse event in VCE. The estimated retention rate is approximately 0.5% at MUHC. To reduce the risk of retention, selected patients (approximately one in every 10 patients) are given a patency capsule (a dummy test capsule that dissolves after some days) prior to the real video capsule one.

**Turnover.** MUHC carries out VCE tests for both internal patients (MGH and RVH) and externally referred patients.

Requests for the VCE test, require the referring specialist to submit a comprehensive 2-page request form, which includes the previous diagnostic tests performed.

The number of VCE procedures has increased from 55 in 2008 to 96 in 2010, with 87 in the first half of 2011(See Figure3). Overall, there were 126 internal requests and 215 external requests (chiefly, CSSS de Laval/Cite de la sante (N=42), Jewish General Hospital (N=35), Haut-Richelieu (N=34), Charles-Lemoyne (N=28), and St-Mary's Hospital (N=12)), including 16 requests from private health centres (Mrs M Diamond) (See Figure 4). The number of external requests has fallen over time due to the acquisition of VCE by other university-affiliated hospital centres. Dr. Seidman expects that the requests will be around 125 VCE plus 12 patency capsules in 2012-2013, and 150 VCE plus 15 patency capsules in 2013-2014.

### 5.2. Budget impact

It is estimated that the unit cost of each VCE (capsules, supplies, human resources and equipment) is approximately \$984.55 (See appendix 5). Thus the gross cost of VCE to the MUHC for approximately 100 cases in fiscal year 2011 would be \$98,455.

It must be noted, however, that each time VCE is not carried out one or more of the alternative diagnostic procedures will have to be used. At the MUHC at this time these include CT Enterography, gastrointestinal angiography, and magnetic resonance enterography, each with a wait time and with approximate unit costs of \$63.2, \$188.4 and \$147, respectively (Nicolas Robert). Furthermore, while each use of VCE costs the MUHC budget a sum of \$984.55, for each alternate diagnostic procedure avoided by use of VCE as result of use of VCE there will be no actual budgetary saving. The beneficial consequence will be a reduction of the wait time for these procedures.

## 6. DISCUSSION

Our report relies on four fairly recent meta-analyses<sup>9-11;20</sup> as a basis for estimates of the risk and effectiveness of this test. Studies which assessed quality found the quality of evidence for the use of VCE in small bowel disease to be low<sup>13;23;27;30;34</sup>. Problems included a lack of consensus concerning the gold standard to be used for small bowel disease and lack of validated criteria for the diagnosis of Crohn's disease using VCE. However, the evidence generally supports the conclusion that in diagnostic yield VCE is the equivalent of, or superior to, the available alternative procedures

However, it should be stressed that a high diagnostic yield is not equivalent to greater diagnostic accuracy, and a high yield may actually be the result of inclusion of false-positive results<sup>35;36</sup>. Furthermore, low diagnostic yield does not necessarily indicate less accuracy, and could result from accurate reflection of a low incidence of the pathology in question. There is some reassurance from the observation that OGIB patients with negative VCE findings, have significantly lower risk of re-bleeding<sup>37</sup>, and for patients with suspected Crohn's disease, normal VCE results suggest that the chances of active small-bowel Crohn's disease is reduced<sup>30</sup>.

It should also be noted that a high diagnostic yield does not necessarily imply beneficial therapeutic impact. A number of observational studies reported that the findings in VCE tests lead to endoscopic or surgical interventions, or medical changes in 22-87% of patients<sup>38-40</sup>. In spite of some variability of the magnitude of impact, most studies concluded that positive VCE results are likely to alter therapeutic strategy and have a positive impact on clinical management.

However, 2 randomized controlled trials (RCTs) did not find the impact of VCE to be superior to alternative diagnostic approaches. De Leusse et al<sup>36</sup> in a (RCT) compared VCE with push enteroscopy for the first line test of OGIB, using intention-to-treat analysis, with a median follow-up of 12 months. The two strategies were not significantly different in terms of diagnostic yield, clinical remission at 1 year, positive therapeutic impact, and additional explorations for both diagnostic and therapeutic purposes. Another RCT by Laine et al 2010<sup>41</sup>, compared the clinical outcomes of

VCE with small bowel radiography for OGIB patients at 1 year follow up. This study found that the improved diagnostic yield by VCE did not result in improvement of clinical outcomes, such as further bleeding, subsequent diagnostic and therapeutic interventions, subsequent hospitalization for bleeding and subsequent blood transfusion.

Finally, selection of the appropriate diagnostic test will depend on numerous factors that can only be properly assessed in the context of a particular case, and the great variability of circumstances makes a protocol to guide the use of VCE extremely difficult to devise.

## **7. CONCLUSIONS**

- **The present evidence is consistent that for the diagnosis of patients with small bowel disease VCE provides a comparable and sometimes higher diagnostic yield than alternative diagnostic approaches.**
- **For patients with OGIB, the diagnostic yield of VCE is significantly higher than that of push enteroscopy, and small bowel barium radiography, and not significantly different from that of double balloon enteroscopy.**
- **For patients with suspected and established small-bowel Crohn's Disease, the diagnostic yield of VCE is significantly higher than that of small bowel barium radiography, CT enterography/enteroclysis, colonoscopy with ileoscopy and push enteroscopy. There is no statistically significant difference in yield between VCE and MRE enterography.**
- **In spite of the absence of data it must be noted that VCE may be associated with overdiagnosis. Two RCTs have demonstrated that compared with other diagnostic tests, VCE did not significantly improve the clinical outcomes in 1 year follow-up.**
- **While the optimal sequence of diagnostic tests must be determined for each case, there is agreement that VCE should not be a first line test.**
- **The unit cost to the MUHC of each VCE study is estimated to be \$984.55. The budget impact of the projected 100 tests per year would therefore be \$98,455. Its use will reduce demand on alternative test procedures, thus diminishing wait times.**

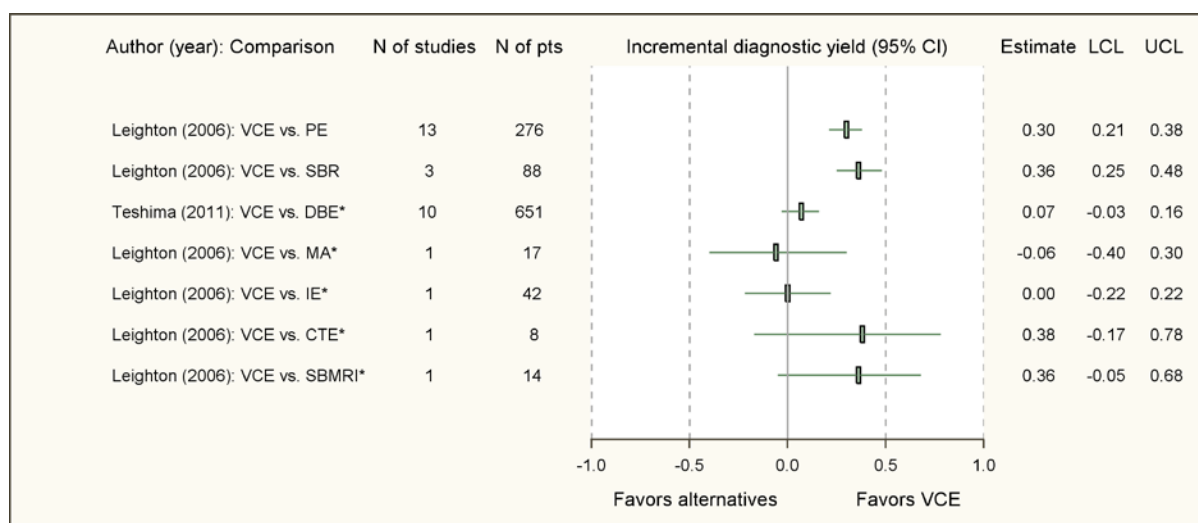
## **8. RECOMMENDATIONS**

- **VCE is now a fully established test for the diagnosis of patients with small bowel disease. It should be available for judicious use at the MUHC. The present practice of using it only when alternate diagnostic modalities have been tried should be maintained.**

- **Due to the substantial budget impact and consequent opportunity costs of a technology which cannot in many cases be justifiably refused, government should be approached with a special request to provide budgetary compensation.**

## FIGURES

**Figure 1: Forest plot of the pooled incremental diagnostic yield of VCE versus alternatives for OGIB**

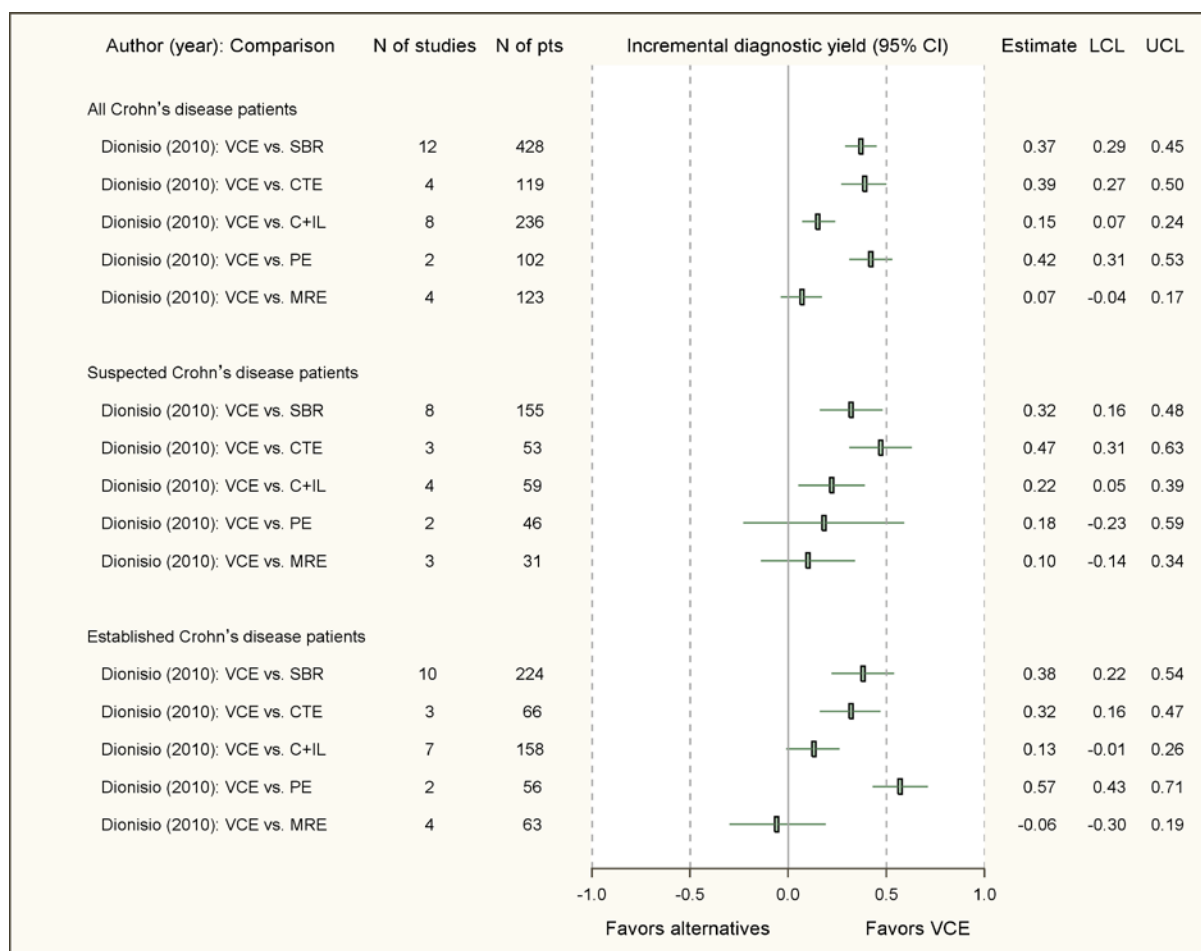


### Abbreviations:

CI= confidence interval; CTE=CT enteroclysis; DBE= double balloon enteroscopy; IE= intraoperative endoscopy; LCL= lower confidence limit; MA= mesenteric angiography; N=number; PE= push enteroscopy; pts= patients; SBMRI= small bowel magnetic resonance imaging; SBR=small bowel barium radiography; UCL= upper confidence limit; VCE= video capsule endoscopy.

\* Note: The pooled risk difference and 95% CI was estimated using random effect meta-analysis (Teshima et al.). For cases where only 1 study was involved, we estimated 95% CI for the difference in two proportions.

**Figure 2: Forest plot of the pooled incremental diagnostic yield of VCE versus alternatives for Crohn's disease**

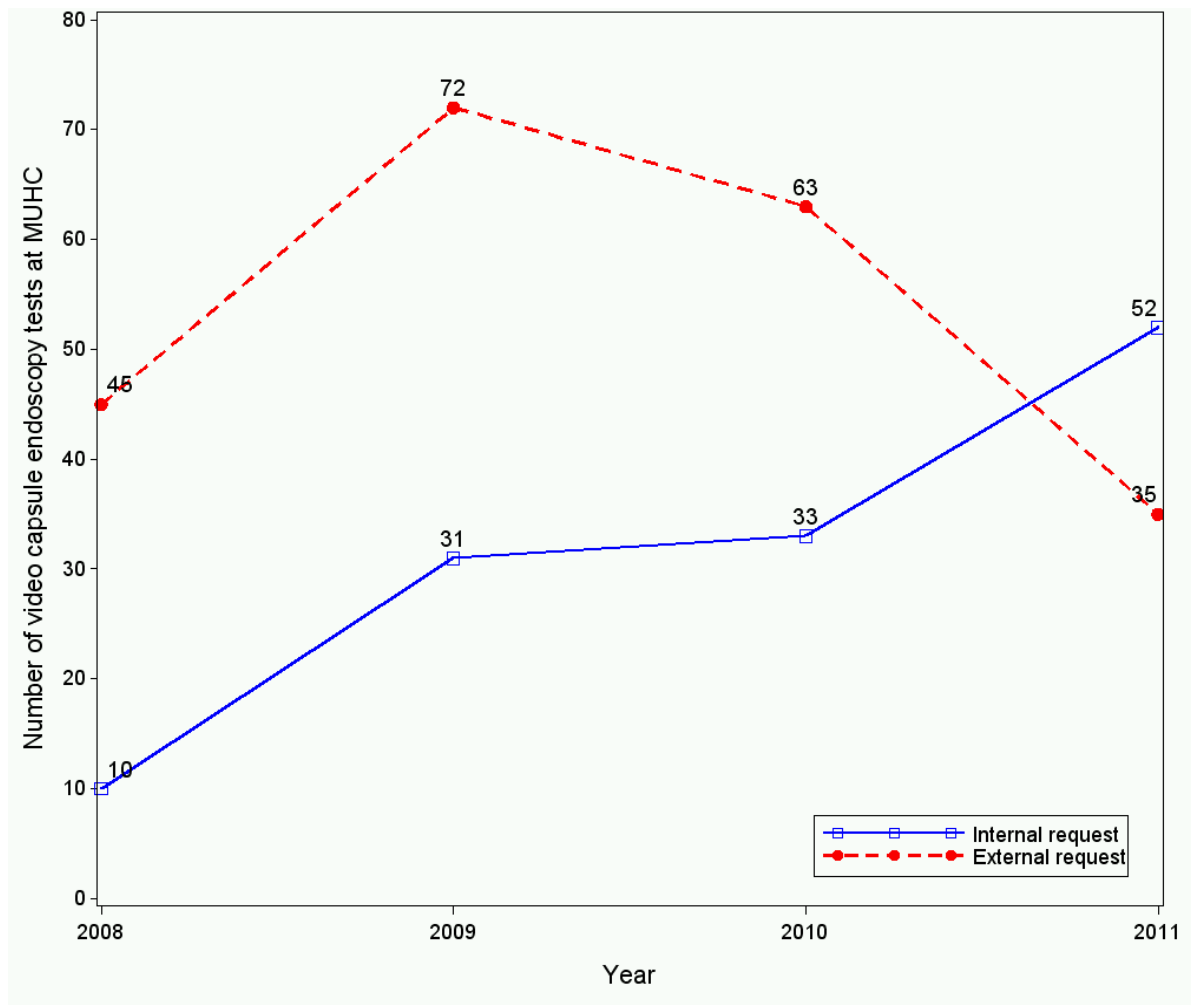


**Abbreviations:**

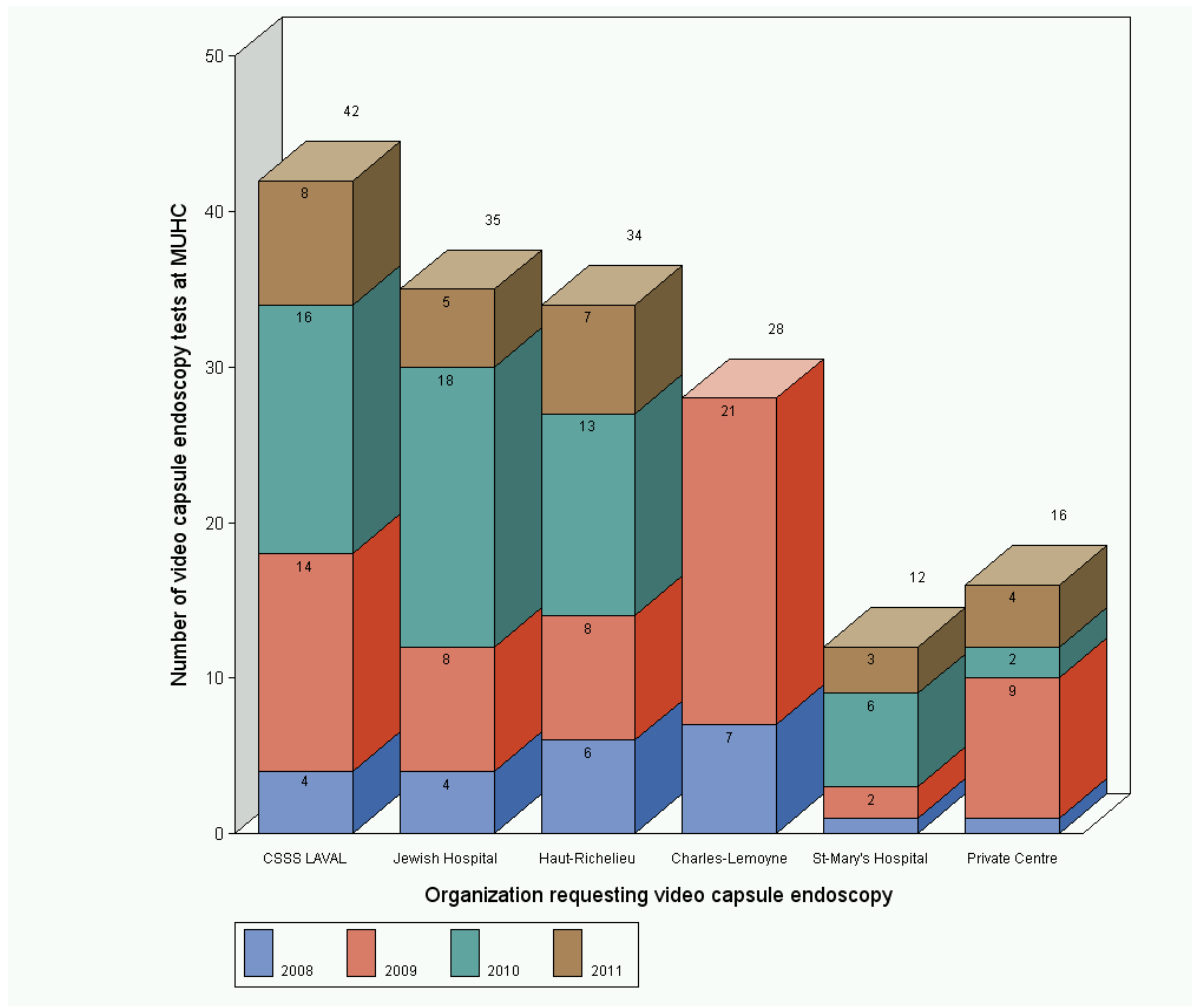
CI= confidence interval; CTE= computed tomography enterography; C + IL=colonoscopy with ileoscopy; LCL= lower confidence limit; MRE=magnetic resonance enterography; N=number; PE= push enteroscopy; pts= patients; SBR=small bowel barium radiography; UCL= upper confidence limit; VCE= video capsule endoscopy.



**Figure 3: Number of VCE procedures carried out at MUHC following internal or external requests (2008 - 2011)**



**Figure 4: Sub-division of externally requested VCE procedures from institutions that made at least 10 requests (2008 - 2011)**



## REFERENCES

- (1) Costa V, Brophy J. Should the MUHC Approve the Video Capsule Endoscopy System in the Diagnosis of Small Bowel Abnormalities? 7, 1-38. 2003. Montreal, Canada, Technology Assessment Unit, McGill University Health Centre.  
Ref Type: Report
- (2) Hailey D, Topfer L.A. Given Diagnostic Imaging System. Emerging Technology List 10. CADTH . [http://www.cadth.ca/media/pdf/given\\_alert\\_e.pdf](http://www.cadth.ca/media/pdf/given_alert_e.pdf) . 2001. 2012.  
Ref Type: Online Source
- (3) Given Imaging. <http://www.givenimaging.com> . 2012. 2012.  
Ref Type: Online Source
- (4) Fritscher-Ravens A, Scherbakov P, Bufler P, Torroni F, Ruuska T, Nuutinen H et al. The feasibility of wireless capsule endoscopy in detecting small intestinal pathology in children under the age of 8 years: a multicentre European study. *Gut* 2009; 58(11):1467-1472.
- (5) Cohen SA, Ephrath H, Lewis JD, Klevens A, Bergwerk A, Liu S et al. Pediatric capsule endoscopy: review of the small bowel and patency capsules. *J Pediatr Gastroenterol Nutr* 2012; 54(3):409-413.
- (6) Cohen SA, Klevens AI. Use of capsule endoscopy in diagnosis and management of pediatric patients, based on meta-analysis. *Clin Gastroenterol Hepatol* 2011; 9(6):490-496.
- (7) University of York. Centre for Reviews and Dissemination. <http://www.crd.york.ac.uk/crdweb/> . 2012.  
Ref Type: Online Source
- (8) Statistics Canada. Consumer Price Index, health and personal care. <http://www.statcan.gc.ca/> . 2012.  
Ref Type: Online Source
- (9) Liao Z, Gao R, Xu C, Li ZS. Indications and detection, completion, and retention rates of small-bowel capsule endoscopy: a systematic review. *Gastrointest Endosc* 2010; 71(2):280-286.
- (10) Dionisio PM, Gurudu SR, Leighton JA, Leontiadis GI, Fleischer DE, Hara AK et al. Capsule endoscopy has a significantly higher diagnostic yield in patients with suspected and established small-bowel Crohn's disease: a meta-analysis. *Am J Gastroenterol* 2010; 105(6):1240-1248.
- (11) Teshima CW, Kuipers EJ, van Zanten SV, Mensink PB. Double balloon enteroscopy and capsule endoscopy for obscure gastrointestinal bleeding: an updated meta-analysis. *J Gastroenterol Hepatol* 2011; 26(5):796-801.

- (12) Westerhof J, Weersma RK, Koornstra JJ. Investigating obscure gastrointestinal bleeding: capsule endoscopy or double balloon enteroscopy? *Neth J Med* 2009; 67(7):260-265.
- (13) Lo SA, Ratti M, Jefferson T, Bernardini F, Cerbo M. Wireless capsule endoscopy in Italy: adding context-specific data to the review of the evidence from literature. *Int J Technol Assess Health Care* 2009; 25(3):297-304.
- (14) Gralnek IM, Leighton JA, Papatheofanis F. Evidence for capsule endoscopy in suspected small bowel Crohn's disease: an evaluation of intergrading system concordance. *J Insur Med* 2009; 41(4):270-283.
- (15) Pasha SF, Leighton JA, Das A, Harrison ME, Decker GA, Fleischer DE et al. Double-balloon enteroscopy and capsule endoscopy have comparable diagnostic yield in small-bowel disease: a meta-analysis. *Clin Gastroenterol Hepatol* 2008; 6(6):671-676.
- (16) Varela LL, Ruano-Ravina A. Effectiveness and safety of capsule endoscopy in the diagnosis of small bowel diseases. *J Clin Gastroenterol* 2008; 42(5):466-471.
- (17) Chen X, Ran ZH, Tong JL. A meta-analysis of the yield of capsule endoscopy compared to double-balloon enteroscopy in patients with small bowel diseases. *World J Gastroenterol* 2007; 13(32):4372-4378.
- (18) Mazzarolo S, Brady P. Small bowel capsule endoscopy: a systematic review. *South Med J* 2007; 100(3):274-280.
- (19) Triester SL, Leighton JA, Leontiadis GI, Gurudu SR, Fleischer DE, Hara AK et al. A meta-analysis of the yield of capsule endoscopy compared to other diagnostic modalities in patients with non-stricturing small bowel Crohn's disease. *Am J Gastroenterol* 2006; 101(5):954-964.
- (20) Leighton JA, Triester SL, Sharma VK. Capsule endoscopy: a meta-analysis for use with obscure gastrointestinal bleeding and Crohn's disease. *Gastrointest Endosc Clin N Am* 2006; 16(2):229-250.
- (21) Triester SL, Leighton JA, Leontiadis GI, Fleischer DE, Hara AK, Heigh RI et al. A meta-analysis of the yield of capsule endoscopy compared to other diagnostic modalities in patients with obscure gastrointestinal bleeding. *Am J Gastroenterol* 2005; 100(11):2407-2418.
- (22) Ziegler KM, Flamm CR, Aronson N. Wireless capsule endoscopy in patients with obscure small-intestinal bleeding. *J Am Coll Radiol* 2005; 2(10):818-820.
- (23) Bernardini F, Cerbo M, Jefferson T, Lo Scalzo A, Ratti M. Wireless capsule endoscopy in the diagnosis of the small bowel disease. 1-179. 2008. Roma, Italy, AGENAS, National Agency for Regional Healthcare.  
Ref Type: Report

- (24) Poelmans J, Hulstaert F, Huybrechts M, Ramaekers D. Capsule endoscopie. Vol. 25A, 1-82. 2006. Brussel-Bruxelles, Belgium, Het Federaal Kenniscentrum voor de Gezondheidszorg, Centre Fédéral d'Expertise des Soins de Santé.  
Ref Type: Report
- (25) National Institute for Health and Clinical Excellence (NICE). Overview of wireless capsule endoscopy. 1-26. 2004. London, United Kingdom, NICE.  
Ref Type: Report
- (26) Oxford Centre for Evidence-based Medicine. Levels of Evidence. <http://www.cebm.net/> . 2012.  
Ref Type: Online Source
- (27) Fisher L, Lee KM, Anderson MA, Appalaneni V, Banerjee S, Ben-Menachem T et al. The role of endoscopy in the management of obscure GI bleeding. *Gastrointest Endosc* 2010; 72(3):471-479.
- (28) Raju GS, Gerson L, Das A, Lewis B. American Gastroenterological Association (AGA) Institute medical position statement on obscure gastrointestinal bleeding. *Gastroenterology* 2007; 133(5):1694-1696.
- (29) Raju GS, Gerson L, Das A, Lewis B. American Gastroenterological Association (AGA) Institute technical review on obscure gastrointestinal bleeding. *Gastroenterology* 2007; 133(5):1697-1717.
- (30) Bourreille A, Ignjatovic A, Aabakken L, Loftus EV, Jr., Eliakim R, Pennazio M et al. Role of small-bowel endoscopy in the management of patients with inflammatory bowel disease: an international OMED-ECCO consensus. *Endoscopy* 2009; 41(7):618-637.
- (31) Lichtenstein GR, Hanauer SB, Sandborn WJ. Management of Crohn's disease in adults. *Am J Gastroenterol* 2009; 104(2):465-483.
- (32) Voderholzer WA, Ortner M, Rogalla P, Beinholz J, Lochs H. Diagnostic yield of wireless capsule enteroscopy in comparison with computed tomography enteroclysis. *Endoscopy* 2003; 35(12):1009-1014.
- (33) Golder SK, Schreyer AG, Endlicher E, Feuerbach S, Scholmerich J, Kullmann F et al. Comparison of capsule endoscopy and magnetic resonance (MR) enteroclysis in suspected small bowel disease. *Int J Colorectal Dis* 2006; 21(2):97-104.
- (34) Sidhu R, Sanders DS, Morris AJ, McAlindon ME. Guidelines on small bowel enteroscopy and capsule endoscopy in adults. *Gut* 2008; 57(1):125-136.
- (35) Lashner BA. Sensitivity-specificity trade-off for capsule endoscopy in IBD: is it worth it? *Am J Gastroenterol* 2006; 101(5):965-966.

- (36) de Leusse A, Vahedi K, Edery J, Tiah D, Fery-Lemonnier E, Cellier C et al. Capsule endoscopy or push enteroscopy for first-line exploration of obscure gastrointestinal bleeding? *Gastroenterology* 2007; 132(3):855-862.
- (37) Iwamoto J, Mizokami Y, Shimokobe K, Yara S, Murakami M, Kido K et al. The clinical outcome of capsule endoscopy in patients with obscure gastrointestinal bleeding. *Hepatogastroenterology* 2011; 58(106):301-305.
- (38) Katsinelos P, Chatzimavroudis G, Terzoudis S, Patsis I, Fasoulas K, Katsinelos T et al. Diagnostic yield and clinical impact of capsule endoscopy in obscure gastrointestinal bleeding during routine clinical practice: a single-center experience. *Med Princ Pract* 2011; 20(1):60-65.
- (39) Cuyle PJ, Schoofs N, Bossuyt P, Moons V, Van OG, Hiele M et al. Single-centre experience on use of videocapsule endoscopy for obscure gastrointestinal bleeding in 120 consecutive patients. *Acta Gastroenterol Belg* 2011; 74(3):400-406.
- (40) Pennazio M, Santucci R, Rondonotti E, Abbiati C, Beccari G, Rossini FP et al. Outcome of patients with obscure gastrointestinal bleeding after capsule endoscopy: report of 100 consecutive cases. *Gastroenterology* 2004; 126(3):643-653.
- (41) Laine L, Sahota A, Shah A. Does capsule endoscopy improve outcomes in obscure gastrointestinal bleeding? Randomized trial versus dedicated small bowel radiography. *Gastroenterology* 2010; 138(5):1673-1680.

## APPENDICES

### Appendix 1: Literature search and study selection

#### Literature search

To identify systematic reviews, we used the following key words in Pubmed: ("obscure GI bleeding" OR "obscure Gastrointestinal bleeding" OR "Crohn's disease" OR "small bowel disease") AND ("capsule endoscopy" OR "video capsule endoscopy" OR "wireless capsule endoscopy" OR "M2A" OR "PillCam") AND ("systematic" OR "systematically" OR "meta" OR "comprehensive"); also, we used "capsule endoscopy" in the York database.

We used the following key words in Pubmed to identify the clinical practice guidelines: ("obscure GI bleeding" OR "obscure Gastrointestinal bleeding" OR "Crohn's disease" OR "small bowel disease") AND ("endoscopy") AND ("standard" OR "guideline" OR "recommendation" OR "Consensus") AND ("literature search" OR "review").

A further search was conducted by tracking references in publications identified. We limited our review to publications appearing in 2004 or later. The last literature search was conducted on March 19<sup>th</sup> 2012.

#### Study selection

Since different reviews were largely based on overlapping studies and arrived at similar conclusions, we did not report duplicated information in this report. When the scientific evidence was consistent, we selected a number of articles representing the entire evidence. The priority was given to articles that:

- Were published more recently
- Were written in English
- Were indexed in the York database
- Provided detailed descriptions of comprehensive literature search and review
- Providing clear definitions of diagnostic yield
- Conducted meta-analysis to synthesize the evidence
- Evaluated the strength of the evidence to support recommendations in clinical guidelines

We excluded systematic reviews or clinical practice guidelines that focused on paediatric patients. When necessary, we tracked the original publications of individual studies to obtain further information.

## Appendix 2: Results of literature search

Thirty-one documents were retrieved. We excluded 17 studies for the following reasons: not a review (n= 6), language not in English (n = 1), expert (narrative) review (n = 7), systematic review for paediatric patients (n= 1), clinical guideline (n = 1) and comment (n=1). The remaining 14 studies were systematic reviews.

We also identified three HTAs<sup>23-25</sup> in English, two from York dataset<sup>24;25</sup> and one<sup>23</sup> by tracking references of a publication<sup>13</sup>. According to the predefined study selection criteria in Appendix 1, we selected 4 meta-analyses for the summary of the evidence of the use of VCE. A brief description of the 10 remaining systematic reviews and 3 HTAs is presented in the Table below.

Table 1: Author and title of 10 systematic reviews and 3 health technology assessments not included in our report

Author (year)	Title
Westerhof (2009) <sup>12</sup>	Investigating obscure gastrointestinal bleeding: capsule endoscopy or double balloon enteroscopy?
Lo Scalzo (2009) <sup>13</sup>	Wireless capsule endoscopy in Italy: adding context-specific data to the review of the evidence from literature
Gralnek (2009) <sup>14</sup>	Evidence for capsule endoscopy in suspected small bowel Crohn's disease: an evaluation of integrating system concordance
Pasha (2008) <sup>15</sup>	Double-balloon enteroscopy and capsule endoscopy have comparable diagnostic yield in small-bowel disease: a meta-analysis
Varela (2008) <sup>16</sup>	Effectiveness and safety of capsule endoscopy in the diagnosis of small bowel diseases
Chen (2007) <sup>17</sup>	A meta-analysis of the yield of capsule endoscopy compared to double-balloon enteroscopy in patients with small bowel diseases
Mazzarolo (2007) <sup>18</sup>	Small bowel capsule endoscopy: a systematic review
Triester (2006) <sup>19</sup>	A meta-analysis of the yield of capsule endoscopy compared to other diagnostic modalities in patients with non-stricturing small bowel Crohn's disease
Triester (2005) <sup>21</sup>	A meta-analysis of the yield of capsule endoscopy compared to other diagnostic modalities in patients with obscure gastrointestinal bleeding
Ziegler (2005) <sup>22</sup>	Wireless capsule endoscopy in patients with obscure small-intestinal bleeding
AGENAS* <sup>23</sup> , Italy (2008)	Wireless capsule endoscopy in the diagnosis of the small bowel disease
KCE <sup>†</sup> <sup>24</sup> ,	Capsule endoscopy



Belgium (2006)	
NICE # <sup>25</sup> , UK (2004)	Overview of wireless capsule endoscopy

\*: AGENAS =National Agency for Regional Healthcare

¶: KCE= Het Federaal Kenniscentrum voor de Gezondheidszorg, Centre Fédéral d'Expertise des Soins de Santé

#: NICE=National Institute for health and Clinical Excellence

### **Appendix 3: Details of diagnostic yield of VCE versus alternatives for OGIB**

#### ***Capsule endoscopy versus push enteroscopy***

Push enteroscopy is a demanding procedure in which the proximal small bowel is examined beyond the pylorus through an extended enteroscope. Leighton et al.<sup>20</sup> identified 13 studies involving 276 patients in which the detection of significant findings by VCE was compared with push enteroscopy. The yield of VCE was 56% versus 26% for push enteroscopy, giving a pooled incremental yield of 30% (95% CI 21%, 38%) in favour of VCE.

In 10 of the 14 studies that reported the types of lesions identified, for vascular lesions VCE had a yield of 36% versus 20% for push enteroscopy, (incremental yield (95% CI):16% (9%, 23%)); and for inflammatory lesions a yield of 11% versus 2% (incremental yield (95% CI): 9% (5%, 13%)). There were no significant differences between the two approaches in detection of tumors and other abnormalities.

#### ***Capsule endoscopy versus small bowel barium radiography***

Leighton et al.<sup>20</sup> identified 3 studies, involving 88 patients, comparing VCE to small bowel barium radiography. The yield of clinically significant findings for VCE was 42% versus 6% for small bowel barium radiography (an incremental pooled yield of 36% (95% CI: 25%, 48%)).

#### ***Capsule endoscopy versus double balloon enteroscopy(DBE)***

Teshima et al. (2011) comparing double balloon enteroscopy (DBE) with VCE for OGIB<sup>11</sup>, identified 10 studies (7 prospective and 3 retrospective), involving 651 patients<sup>11</sup>. The pooled yield for VCE and DBE was 62% (95%CI: 47%, 76%) and 56% (95%CI: 49%, 62%), respectively, with an odds ratio (OR) of 1.39 (95%CI: 0.88, 2.20).

#### ***Capsule endoscopy versus intraoperative endoscopy, mesenteric angiography, CT enteroclysis, and small bowel MRI***

Leighton et al.<sup>20</sup> identified 3 studies in which VCE was compared with these four alternative diagnostic procedures. They found a total yield of 47% for VCE versus 53% for mesenteric angiography (n = 17, not statistically different); for VCE and intraoperative endoscopy the yield (n = 42) was identical, 83%; the yield of 50% for VCE versus 12.5% for CT enteroclysis (n = 8)<sup>32</sup> was not statistically different; and the yield of VCE was significantly higher than that of small bowel MRI(n = 14)<sup>33</sup>, 36% versus 0% (p=0.007).

## **Appendix 4: Details of diagnostic yield of VCE versus alternatives for Crohn's disease**

### ***VCE versus small bowel barium radiography (SBR)***

Dionisio et al.<sup>10</sup> identified 12 studies, involving 428 patients in which this comparison was possible. For all patients, the diagnostic yield of Crohn's disease by VCE was 58% and by SBR, 22%, with a pooled incremental yield (95% CI) of 37% (29%, 45%). For suspected Crohn's disease (8 studies, 155 patients), the diagnostic yield by VCE was 52% and by SBR, 16%, with an incremental yield (95% CI) of 32% (16%, 48%); and for the established Crohn's disease (10 studies, 224 patients), the diagnostic yield for VCE was 71% and 36% for SBR, with an incremental yield (95% CI) of 38% (22%, 54%).

### ***VCE versus CT enterography / enteroclysis (CTE)***

Dionisio et al.<sup>10</sup> identified 4 trials involving 119 patients. For all Crohn's disease patients, VCE had a 70% yield compared with a 31% yield for CTE, with a pooled incremental yield (95% CI) of 39% (27%, 50%). In 3 studies of 53 suspected Crohn's disease subjects, VCE had a 68% yield, compared to a 21% yield for CTE, resulting in a pooled incremental yield (95% CI) of 47% (31%, 63%). For established Crohn's disease (3 studies, 66 patients), the yield was 71% for VCE and 39% for CTE, with a pooled incremental yield (95% CI) of 32% (16%, 47%).

### ***VCE versus colonoscopy with ileoscopy***

Dionisio et al.<sup>10</sup> identified 8 trials of 236 patients that compared VCE with colonoscopy and ileoscopy. The yield for Crohn's disease was 64% for VCE, compared with 48% for colonoscopy and ileoscopy, and the pooled incremental yield (95% CI) by VCE was 15% (7%, 24%). In 4 trials involving 59 suspected Crohn's disease patients, VCE had a yield of 47% versus 25% with colonoscopy and ileoscopy, a pooled incremental yield (95% CI) of 22% (5%, 39%). In 7 studies involving 158 established Crohn's disease patients, VCE had a yield of 70% versus 57% with colonoscopy with ileoscopy, with a pooled incremental yield (95% CI) of 13% (-1%, 26%).

### ***VCE versus push enteroscopy***

In two studies (102 patients)<sup>10</sup> VCE was compared with push enteroscopy. For all patients with Crohn's disease, VCE had a yield of 50% versus 8% for push enteroscopy, with a pooled incremental yield (95% CI) of 42% (31%, 53%); for 46 patients with suspected Crohn's disease, the yield for VCE and push enteroscopy was 33% and 9%, respectively, with a pooled incremental yield (95% CI) of 18% (-23% to 59%); and for 56 established Crohn's disease patients, VCE had a yield of 66% versus 9% for push enteroscopy, with a pooled incremental yield (95% CI) of 57% (43%, 71%).

***VCE versus Magnetic Resonance Enterography(MRE)***

Dionisio et al. identified 4 trials (123 patients) that compared VCE with MRE. There were no statistically significant differences in yields between the two diagnostic tests for all Crohn's disease patients or subgroups. For all Crohn's disease patients, VCE had a yield of 50% versus 43% for MRE, with a pooled incremental yield (95% CI) of 7% (-4%, 17%). In 3 studies involving 31 suspected Crohn's disease patients, the yield for VCE was 55% versus 45% for MR enterography, with a pooled incremental yield (95% CI) of 7% (-14%, 34%); and in four studies involving 63 established VCE patients, the yield for VCE was 70% versus 79% for MR enterography, with a pooled incremental yield (95% CI) of -6% (-30%, 19%).

## Appendix 5: Costs of VCE procedure

The estimated procedure costs of VCE are summarized in the tables below.

Table 2: Estimated cost of VCE

	<b>Breakdown of VCE costs (\$)</b>	<b>Estimated cost per procedure (\$)</b>
<b>Human resources</b> (for 3-4 procedure per week)	VCE technician: 25 hours per week at 28/hour; Administrator: 15 hours per week at 28/hour	$320 = ((25+15) \times 28) / 3.5$
<b>Capsule</b>	Cost before taxes Agile – 5 / pack: 900 SB2 – 10 / pack: 5,600 (2 packs with 5 free) Colon– 10 / pack: 5,494.5	492.56 (after tax) #
<b>Telephone</b>	624 / year	6.24*
<b>Office supplies</b>	1,000 / year	10*
<b>Capital equipment<sup>@</sup></b>	Equivalent annual cost: 15,575	155.75*
<b>Total</b>	--	<b>984.55</b>

#: About 10% of patients receive patency capsules (Agile) because they are considered to be at high risk of capsule retention. A few patients (<10 per year) receive Colon capsules that permit examination of the colon. MUHC pays 5.7% tax for medical devices (Nicolas Robert). The estimated capsule cost per procedure =  $((900/5) \times 0.1 + (5600 \times 2/25)) \times 1.057$ .

\*: Based on an assumed 100 VCE procedures per year.

@: The capital equipment includes a specialized workstation, sensor belt, Given software for reading the images from the capsule data recorder and real time viewer. Details of estimated equivalent annual cost can be found in Table 3.

Table 3: Cost of Capital Equipment for VCE procedures

<b>Hardware</b>	<b>Unit Cost (\$)</b>	<b>Number of units</b>	<b>Expected service life of new equipment (year)</b>	<b>Equivalent annual cost* (\$)</b>
Real time viewer	2,165	1	5	503.39
Software upgrade	2,995	1	4	850.26
Rapid 7 workstation	23,445	1	5	5,451.31
Data recorder 3	6,495	2	5	3,020.37
Data recorder 3 sensor belt	910	2	4	516.68
Data recorder 2	6,495	3	5	4,530.55
Data recorder 2 sensor belt	825	3	4	702.63
<b>Total</b>	--	--	--	<b>15,575</b>

\*: The annual discount rate of 5% is used in the calculation of equivalent annual cost (EAC). The EAC estimates included 5.7% tax for purchasing medical devices by MUHC.